

# Scorpion sting in southern Africa: diagnosis and management

*Only a few local scorpions are dangerous, but those that are can cause life-threatening envenoming.*

## GJ Müller, BSc, MB ChB, Hons BSc (Pharm), MMed (Anaes), PhD (Tox)

Dr Müller is part-time consultant in the Division of Pharmacology, Department of Medicine, Faculty of Medicine and Health Sciences, Stellenbosch University. He is the founder of the Tygerberg Poison Information Centre.

## H Modler, Dip Pharm (Pharmacy), BSc, MB ChB, MMed (Anaes)

Dr Modler is an anaesthetist in private practice, as well as a part-time lecturer and external examiner in pharmacology at the Department of Anaesthesia, Stellenbosch University and the Colleges of Medicine of South Africa.

## CA Wium, MSc Medical Sciences

Ms Wium is a principal medical scientist employed as a toxicologist in the Tygerberg Poison Information Centre, Division of Pharmacology, Department of Medicine, Faculty of Medicine and Health Sciences, Stellenbosch University.

## DJH Veale, PhD Pharmacology

Dr Veale is the former director of the Tygerberg Poison Information Centre and currently a consultant clinical pharmacist and lecturer in pharmacology and toxicology.

Correspondence to: Gert Müller (gmul@sun.ac.za)

Most southern African scorpions are relatively harmless to humans, and although they can inflict quite a painful sting, no other toxic effects are expected to develop. However, a small number of scorpion species can cause life-threatening systemic envenoming. Children are especially vulnerable, with a mortality rate of close to 20%. Most deaths are attributable to one species, namely *Parabuthus granulatus*. In order for medical personnel to provide optimal patient management after a scorpion sting, they should be familiar with the clinical picture and management.

Four scorpion families have been identified in southern Africa: Scorpionidae, Buthidae, Bothriuridae and Liochelidae. Of these, Scorpionidae (42%) and Buthidae (34%) are the most abundant and responsible for most scorpion stings. The potentially dangerous and medically important species all belong to the Buthidae family. The Buthidae are easily distinguishable from the Scorpionidae by their thick tails and slender pincers (pedipalps), whereas the relatively harmless Scorpionidae have large, powerful pincers and thin tails. Seven genera have been identified in the Buthidae family. The genus *Parabuthus* is medically the most important. Of the 22 *Parabuthus* species that occur in southern Africa, only two, namely *P. granulatus* and *P. transvaalicus* have been shown to be associated with serious envenomings. From recent

LD<sub>50</sub> studies in mice it has been shown that *P. granulatus* is three times more venomous than *P. transvaalicus*. Clinical studies have also found that *P. granulatus* envenoming is associated with a higher morbidity and mortality compared with *P. transvaalicus*.

Identification of a scorpion down to species level is difficult and can only be done by an expert. The traditional rule of thumb that scorpions with thick tails and slender pincers (Buthidae) are more venomous than those with slender tails and large pincers (Scorpionidae) is a useful guide for the clinician (Fig. 1).



Fig. 1. Left: the potentially lethal *Parabuthus granulatus* scorpion, displaying slender pincers (pedipalps) and a relatively thick 'tail'. Right: a scorpion species of the relatively harmless Scorpionidae family, displaying large, powerful pincers (pedipalps) and a thin 'tail'.

*P. granulatus* and *P. transvaalicus* are very large scorpions, measuring 60 - 150 mm in length. *P. granulatus* is light to dark brown in colour whereas *P. transvaalicus* is dark brown to uniformly black.

Scorpion venom is injected by means of a stinger located at the tip of the telson, the terminal segment of the 'tail'. The bulbous portion of the telson, also known as the vesicle, contains two venom glands, each with a duct opening on each side near the tip of the stinger. During the stinging process, muscles attached to the exoskeleton on each side of the gland contract, injecting the venom through the orifices. The general morphology of scorpions is shown in Fig. 2. Distribution maps are given in Fig. 3.

Scorpions are mostly active during the summer months and most species are nocturnal. *Parabuthus* species dig shallow burrows or scrapes at the base of shrubs, under rocks or fallen trees, and in soils of variable hardness and texture ranging from consolidated sand to moderately hard and gritty sediments. Some, for example *P. granulatus*, are often found near human habitats (e.g. suburban gardens and farm yards).

The clinical profile of scorpionism primarily reflects a state of generalised neurological

## Scorpion sting




Fig. 2. General morphology of *Parabuthus granulatus* and *P. transvaalicus*.

hyperexcitability. Other excitable tissue, such as skeletal and heart muscle, may also be affected. Scorpion venoms are complex aqueous mixtures containing mucus, inorganic salts, low-molecular-weight organic molecules and many different small basic proteins ( $M_r$  8000), which are the neurotoxins. The neurotoxins act on sodium channels of excitable cells, either by retarding inactivation (an  $\alpha$ -toxin) or enhancing activation (a  $\beta$ -toxin) leading to spontaneous depolarisation of excitable cells. The overall effect is a tendency of the neuron to fire spontaneously and repetitively. Noradrenaline and acetylcholine are released from adrenergic and cholinergic nerve endings, respectively, and adrenaline is released from the adrenal medulla. These mechanisms may explain the sympathetic, para-sympathetic and skeletal muscle effects of scorpion venom. Symptoms and signs of increased sympathetic activity include hypertension, tachycardia, cardiac dysrhythmias, increased perspiration, fever, hyperglycaemia and restlessness. An increase in catecholamine levels has been demonstrated in severe envenomings. Hypertension may also be induced by an increase in renin release. Parasympathetic effects include increased salivation, bradycardia, hypotension and gastric distension. Tremors and involuntary

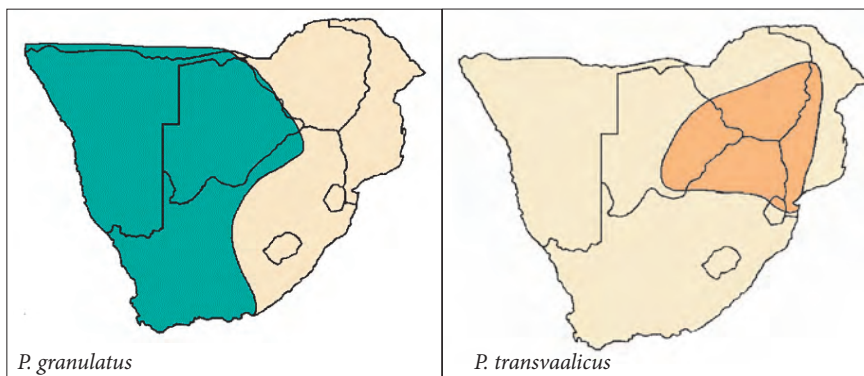


Fig. 3. Distribution maps of *Parabuthus granulatus* and *P. transvaalicus*.

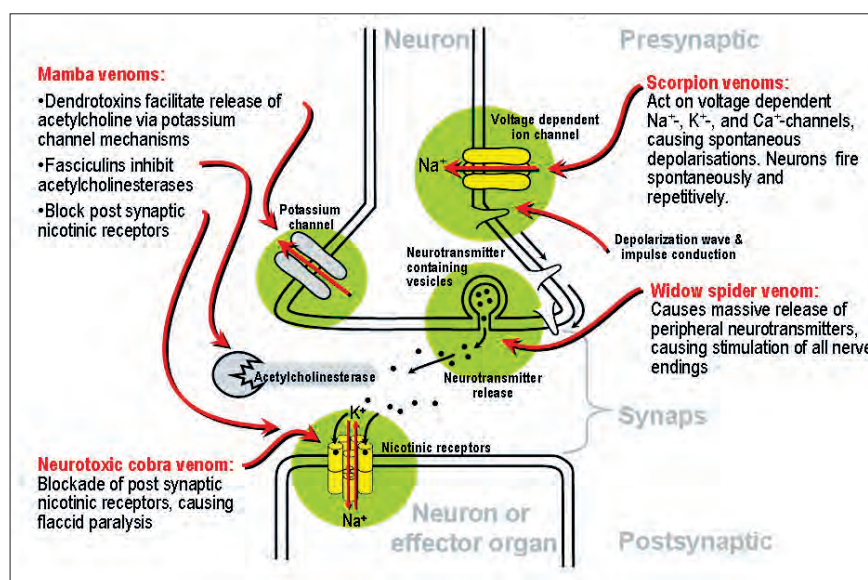


Fig. 4. Mechanisms of action of neurotoxic venoms on the peripheral nervous system.

movements seen in scorpionism are due to excessive somatic neuromuscular activity. Muscle weakness, difficulty in breathing and bulbar paralysis could be explained by a phase of relative neurotransmitter depletion after excessive neuronal activity. See Fig. 4 with regard to the mechanism of action of neurotoxic venoms on the peripheral nervous system.

### Diagnosis and clinical profile of scorpionism

The spectrum and degree of symptoms and signs of systemic envenoming are determined by several factors:

- the scorpion species involved
- the body mass of the victim (children are more vulnerable than adults)
- the amount of venom injected
- the physical health of the patient.

The clinical presentation of scorpionism in the under-13-year-old age group differs in many respects from that in the older patient (>13 years).

**Most deaths are attributable to one species, namely, *Parabuthus granulatus*.**

Typically, the victim, barefoot or wearing sandals at the time of the incident, is stung on the foot after sundown, usually outside the home. Immediate pain is the most prominent symptom, often described as burning and of an excruciating intensity. The pain lasts for a variable period, usually extending from

## Scorpion sting

hours to a day and sometimes even longer. It is usually accompanied by local paraesthesia and pronounced hyperaesthesia. In the normal course most adult patients become aware of paraesthesia in the hands and feet within 1 - 4 hours of being stung. Although paraesthesia may become general it is often experienced in the scalp, around the mouth or in other areas of the face. Generalised hyperaesthesia, muscle pain and cramps are prominent. Every movement and surface contact, such as friction from sheets and bed clothes, causes pain. Some patients describe a sensation of vibration and experience a feeling akin to an electrical current moving through the body, and many complain of difficulty in swallowing and increased salivation.

**From recent LD<sup>50</sup> studies in mice it has been shown that *P. granulatus* is three times more venomous than *P. transvaalicus*.**

General weakness, reflected by difficulty in walking, is a common symptom. Some patients experience visual disturbances and a substantial number have difficulty breathing.

On examination, the adult patient is anxious and obviously in pain. Tremors and involuntary movements are pronounced. Bulbar paralysis is characterised by dysphagia, dysarthria and drooling, with varying degrees of loss of pharyngeal reflexes. Increased salivation is typical. The blood pressure and temperature are often raised and the tendon reflexes are hyper-reactive. The relaxation phase of the ankle reflex is occasionally delayed, and clonus may be present.

There is a general decrease in motor power and if the adult patient is able to walk at all, he or she does so ataxically in a gait similar to that seen in alcohol intoxication. Some patients walk in a stiff-legged manner as

if to avoid bending their knees. Ptosis, an increase in perspiration and retention of urine may be present in a substantial number of patients. A cold clammy skin is sometimes prominent.

In adults development of systemic symptoms and signs may occasionally be delayed up to 8 hours after the sting.

Although children may present with symptoms and signs similar to those seen in adults, the most outstanding clinical feature is a unique form of restlessness. The restlessness should not simply be interpreted as a reaction to pain but should rather be recognised as a severe form of systemic envenomation. It is characterised by crying and screaming, uncontrollable jerking of the extremities, chaotic thrashing movements, flailing and writhing. The patient is unable to lie still and is difficult to restrain. He or she may assume an unnatural posture and contract the face in a simulated chewing motion, with grimaces and smacking of the lips. The behaviour is completely out of character and abnormal to the extent that those present gather to observe the spectacle. Excessive neuromuscular activity may sometimes be mistaken for convulsions or mimic the central effects of an overdose of neuroleptics, tricyclic antidepressants or anticholinergics. The restlessness caused by scorpionism in children has been described as 'extraordinary and duplicated by little else in medicine'. The smaller child or infant may, however, present with unexplained crying only.

Bulbar paralysis, accompanied by respiratory distress, is more frequent in children than in adults and tends to be more severe. Respiratory failure is the most dangerous feature of severe scorpionism and is usually the primary cause of death. Severe cardiovascular manifestations such as cardiac dysrhythmias, pulmonary oedema and cardiac failure, which are often associated with scorpionism in other regions of the world, are not such a prominent feature in southern Africa. Although a high percentage of patients present with raised blood pressure, this is not a consistent finding.

Although the sting site can usually be identified, the local reaction is mild and often unimpressive. In some cases it may even be difficult to locate the sting site.

### Differential diagnosis

The diagnosis of scorpionism can sometimes be difficult in the absence of a firm history of a sting and particularly in children. Conditions which should be considered in a differential diagnosis are listed in Table I, where the major symptoms and signs of scorpionism, latrodectism and neurotoxic cobra bite are compared.

**The clinical profile of scorpionism primarily reflects a state of generalised neurological hyperexcitability.**

## Scorpion sting

**Table 1. Comparison of major symptoms and signs of scorpionism, latrodectism and neurotoxic cobra bite**

Symptoms and signs of envenomation	Scorpionism	Latrodectism	Neurotoxic cobra bite
<b>Local symptoms and signs</b>	(+)	+	++
Degree of local physical signs (bite or sting site)	++++	+	++
Local pain	+	+++	+
Regional lymph nodes, pain and swelling			
<b>Systemic symptoms and signs</b>	++(+)	++++	-
Generalised muscular pain	+(+)	+++	-
Muscle tone: extremities, abdomen and chest	++++	+	-
Paraesthesia, hyperaesthesia	++++	-	+++
Dysphagia, dysarthria,	++++	++	+
Involuntary movements, tremor, fasciculations	++++*	++	-
Hyperactivity, restlessness	+++	++	-
Stretch reflexes	-	-	++++
Flaccid paralysis	+++*	-	++++
Difficulty in breathing, requiring vent. support	(+)	-	++++
Ophthalmoplegia	++	-	++++
Ptosis			
Autonomic dysfunction:	+++**	+++	(+)
• pulse rate: fast or slow, ↑ blood pressure	++	+++(+)	+
• sweating ↑	++	+	(+)
• temperature ↑	++++	-	++
• salivation ↑ upper respiratory secretions*			

\* Children especially.

\*\* Species differences, e.g. *P. granulatus*: ↑ pulse rate; *P. transvaalicus*: ↓ pulse rate.

### Spider bite

Although different mechanisms of action are involved, both scorpion and widow spider venoms (genus: *Latrodectus*) cause an increase in the release of peripheral neurotransmitters, resulting in some similarities between latrodectism and scorpionism. Classic symptoms and signs of scorpionism usually not found in latrodectism include dysphagia with marked oro-pharyngeal secretions, difficulty in breathing, visual disturbances and pronounced general hyperaesthesia. Profuse sweating and abdominal muscle rigidity, on the other hand, are much more prominent in latrodectism. Cytotoxic spider bites are not associated with neurotoxic effects and are therefore not considered in the differential diagnosis.

### Snake bite

In a substantial number of neurotoxic snake bites, as in scorpion sting, the bite site is either insignificant or cannot be located. Both mamba and Cape cobra bites can cause visual disturbances, ptosis and dysphagia as well as difficulty in breathing in the early stages of envenomation. Most patients

will, however, rapidly progress to a state of complete flaccid paralysis within 1 - 4 hours. Although berg adder venom, which is partly neurotoxic, can induce marked ptosis and occasionally dysphagia, other prominent symptoms and signs include complete ophthalmoplegia, disturbances of smell and taste and hyponatraemia. A local inflammatory reaction with marked swelling is also typical of berg adder bite but usually absent in scorpion sting.

**The patient should be assessed continuously for the development of neurotoxic complications.**

### Poisoning caused by cholinesterase inhibitors

Organophosphate as well as carbamate poisoning and scorpion envenoming can cause a state of anxiety and restlessness,



## Scorpion sting

muscle twitching, increased oro-pharyngeal secretions, decrease in motor power, raised blood pressure, tachycardia and respiratory distress. It is possible that an increase in the concentration of acetylcholine in the synaptic cleft, induced by both scorpion venom and organophosphate poisoning, is responsible for many of the similarities.

### Drug overdose

Neuroleptic drug overdose in children typically presents with confusion, restlessness, slurred speech, dysarthria, difficulty in swallowing, painless spasms, hypertonicity and tremors. However, an increase in oro-pharyngeal secretions, a prominent feature of scorpion sting, is not associated with an overdose of these agents. Other types of drug overdose to be considered in children with restlessness, hyperactivity and abnormal behaviour are the anticholinergics and tricyclic antidepressants.

### Guillain-Barré syndrome

This syndrome is characterised by a rapid onset of peripheral and cranial nerve dysfunction. Both scorpionism and the

Guillain-Barré syndrome can present with paraesthesia, decreased motor power, dysphagia, dysarthria, autonomic nervous system dysfunction and respiratory distress. Scorpionism is usually more rapid in onset.

### Tetanus

Although tetanus is characterised by pronounced rigidity and reflex muscle spasm, excessive muscle activity of early or milder forms of tetanus could conceivably be confused with those seen in severe scorpionism. Both tetanus and scorpionism can present with dysphagia and excessive oro-pharyngeal secretions, respiratory distress and autonomic nervous system instability characterised by tachycardia, sweating and wide variations in blood pressure.

**The traditional rule of thumb that scorpions with thick tails and slender pincers (Buthidae) are more venomous than those with slender tails and large pincers (Scorpionidae) is a useful guide for the clinician.**

### Other conditions

Other clinical conditions that should be considered in the differential diagnosis include poliomyelitis, botulism, myasthenia gravis, encephalitis, meningitis, subdural haematoma and diphtheria.

### Management

Scorpionism (scorpion sting associated with symptoms and signs of systemic envenoming) is a medical emergency. Successful clinical management of scorpionism is dependent upon a proper assessment of the circumstances, speed of onset and an awareness of the potentially serious neurotoxic effects.

In most cases the degree of severity of scorpion envenoming is evident quite soon after the sting (within 15 - 60 minutes). The reduction or loss of upper respiratory protective reflexes and the development of respiratory distress are the most serious complications of scorpionism. Patients, especially children, may develop respiratory failure within 1 - 2 hours. First aid should therefore focus on respiratory support. The patient should be assessed continuously for the development of neurotoxic complications. While instituting first aid procedures, where applicable, transport should be organised to a medical facility as soon as possible. The medical facility or doctor should be alerted ahead of the arrival of the patient. It should be emphasised that transport of the symptomatic patient without the necessary airway protection facilities and appropriate management capabilities is potentially dangerous. A significant number of children die on their way to hospital due to inadequate first aid procedures.

As scorpion venom induces autonomic nervous system instability, patients with serious envenoming should be closely monitored for the development of cardiac dysrhythmias, severe hypertension or hypotension. The use of atropine to reduce secretions is not advisable as this may lead to unopposed adrenergic responses. Intravenous fluid therapy should also be closely supervised to prevent vascular overload.

Children presenting with restlessness should not be given any central nervous system depressants, e.g. opioids or benzodiazepines. These will not only aggravate the respiratory depression but may increase the risk of vomiting and aspiration. However, sedation may be indicated to allow intubation and ventilation.

The only effective treatment for the severe local pain is infiltration of the sting site with a local anaesthetic agent. Opioids are relatively ineffective and increase the risk of respiratory depression. Experience with non-steroidal anti-inflammatory agents is also disappointing. Although some authors

## Scorpion sting

recommend that crushed ice be applied to the sting site, most patients will not allow this due to local hyperaesthesia. Slow intravenous administration of calcium gluconate 10% (10 ml over 5 - 10 min) is moderately effective for the relief of generalised muscle pain and cramps, but its effect lasts for 20 - 30 minutes only and there is a limit to the amount that can be administered safely.

**Successful clinical management of scorpionism is dependent upon a proper assessment of the circumstances, speed of onset and an awareness of the potentially serious neurotoxic effects.**

The routine use of antihistamines and glucocorticosteroids is not recommended unless they are administered to decrease the

severity of a possible allergic reaction to the antivenom.

Although the identification of the scorpion involved is useful in the management of the patient, the specimen is often not available (available in 10 - 20% of cases at best). If available, it is recommended that the scorpion be taken to the hospital with the patient for identification.

In cases where the scorpion has not been identified, it is recommended that the asymptomatic child be admitted to a medical facility for observation for at least 12 hours.

Scorpion antivenom should be given to all patients with symptoms and signs of systemic envenoming. The scorpion antivenom (SAIMR Scorpion Venom Antiserum SAVP) is a refined equine anti-scorpion serum globulin supplied in 5 ml ampoules. The standard dose is 5 - 10 ml intravenously for both adults and children. It usually takes 2 - 6 hours to reach its peak effect and therefore respiratory support is life-saving in the interim period. Occasionally an additional dose of 5 ml

may be administered after 6 hours should the response to the first dose be inadequate. Allergic/anaphylactoid reactions to the antivenom may develop, as is the case with all serum preparations of animal origin. The prophylactic administration of adrenaline intramuscularly to prevent serious allergic reactions is controversial because it may increase the effects of sympathetic nervous system stimulation by the scorpion venom. The victim should be kept under observation for 6 - 12 hours after antivenom administration.

See general instructions with regard to antivenom therapy, management of allergic reactions and the prophylactic use of adrenaline in the prevention of allergic reactions in the snake bite article.

Special investigations which may assist in assessment and treatment include: pH and electrolytes, acid-base balance, arterial blood gasses and an ECG where applicable.

Further reading available at [www.cmej.org.za](http://www.cmej.org.za)

### IN A NUTSHELL

- Most local scorpions are relatively harmless, and although they can inflict quite a painful sting, other toxic effects are not expected to develop.
- However, a small number of scorpion species can cause life-threatening systemic envenoming.
- Most deaths are attributable to one species, namely *Parabuthus granulatus*.
- Children are especially vulnerable, with a mortality rate of close to 20%.
- The traditional rule of thumb that scorpions with thick tails and slender pincers (Buthidae) are more venomous than those with slender tails and large pincers (Scorpionidae) is a useful guide for the clinician.
- The clinical profile of scorpionism primarily reflects a state of generalised neurological hyperexcitability.
- Although children may present with symptoms and signs similar to those seen in adults, the most outstanding clinical feature is a unique form of restlessness.
- Respiratory failure is the most dangerous feature of severe scorpionism and is usually the primary cause of death.
- The diagnosis of scorpionism can sometimes be difficult in the absence of a firm history of a sting, particularly in children.
- Conditions which should be considered in the differential diagnosis include neurotoxic spider and snake bite.
- In cases where the scorpion has not been identified, it is recommended that the asymptomatic child be admitted to a medical facility for observation for at least 12 hours.
- Scorpion antivenom should be given to all patients with symptoms and signs of systemic envenoming.
- Allergic/anaphylactoid reactions to the antivenom may occur.